

DISCHARGING MASTOID CAVITY: A CLINICAL ANALYSIS

B. Y. Praveen Kumar¹, K. M. Govinde Gowda², M. K. Veena Pani³, Shilpa Tubajirao Hotkar⁴, Neelesh Tiwari⁵, Thanzeemunisa⁶

HOW TO CITE THIS ARTICLE:

B. Y. Praveen Kumar, K. M. Govinde Gowda, M. K. Veena Pani, Shilpa Tubajirao Hotkar, Neelesh Tiwari, Thanzeemunisa. "Discharging Mastoid Cavity: A Clinical Analysis". Journal of Evolution of Medical and Dental Sciences 2015; Vol. 4, Issue 37, May 07; Page: 6390-6397, DOI: 10.14260/jemds/2015/929

ABSTRACT: CONTEXT: A discharging mastoid cavity is a frustrating condition for both patient and surgeon and can occur after a canal wall down mastoidectomy operation. **AIMS:** To determine the percentage of patients having a discharging mastoid cavity and to establish the aetiological factors responsible for it. **SETTING:** Academic tertiary care referral institution. **DESIGN:** Prospective study **MATERIALS AND METHODS:** One hundred and sixty nine patients with chronic suppurative otitis media with cholesteatoma who underwent a canal wall down mastoidectomy were included in the study. These patients were regularly followed up to detect the occurrence of discharging mastoid cavity. **RESULTS:** Forty one (24.26%) patients had a discharging mastoid cavity after a mean follow up of 4.2 years. The main causes were tympanic membrane perforation with exposed middle ear mucosa and open eustachian tube in thirty two patients (78.04%), followed by meatal stenosis in twenty five patients (60.97%) and high facial ridge in twenty patients (48.78%). **CONCLUSIONS:** Tympanic membrane perforation with exposure of middle ear mucosa, meatal stenosis and a high facial ridge are important causes for a discharging mastoid cavity.

KEYWORDS: Discharging mastoid cavity, Canal wall down mastoidectomy.

INTRODUCTION: Modified radical mastoidectomy is a well-established technique for the treatment of chronic suppurative otitis media with cholesteatoma. This procedure can have failures in the form of a discharging mastoid cavity. A chronically draining cavity is a frustrating problem for the patient and a difficult condition to manage for the otologist. A regular long term follow-up for many years is required to detect failures. Causes for a discharging mastoid cavity should be critically analyzed and addressed during surgery to prevent this unfavourable situation.

MATERIALS AND METHODS: Study Design and Setting: This is a prospective study conducted on 169 patients between November 2006 and April 2014 (7 years and 6 months) at Krishnarajendra Hospital, Mysore an Academic Tertiary care referral hospital.

AIMS OF THE STUDY:

1. To determine the percentage of patients having discharging mastoid cavity.
2. To evaluate the causes for discharging mastoid cavity.

Inclusion Criteria: Patients with chronic suppurative otitis media with cholesteatoma involving the middle ear and mastoid.

Exclusion Criteria: Patients with cholesteatoma recidivism were not included in the study since these patients had a prior surgical failure. None of the patients in this study had indications which required a radical mastoidectomy.

ORIGINAL ARTICLE

A thorough history was elicited and an ENT examination including microscopic examination of the ear was done. An aural swab for culture and sensitivity was taken. Routine haematological and urine examination was performed. A pure tone audiometry was done to assess the hearing status. Under local or general anaesthesia a modified radical mastoidectomy,⁽¹⁾ was performed and cholesteatoma from the middle ear and mastoid was excised. Ossicular reconstruction was performed in the following manner. If the stapes head was present, the temporalis fascia graft was placed on the stapes head. If the stapes suprastructure was eroded by disease, a long collumella ossiculoplasty using sculptured homograft septal spur cartilage was performed followed by temporalis fascia grafting. Gelfoam was placed on the fascia, a meatoplasty was performed and the mastoid bowl was packed with ribbon gauze smeared with antibiotic ointment. Postoperatively appropriate antibiotics were administered for a week.

The ear packing was removed after 2 weeks. Broad spectrum antibiotic ear drops were prescribed for 3 weeks and the patients were instructed to prevent water entry into the ear. All patients were followed up monthly for the first six months. During the next eighteen months, follow up was done at three month intervals. Follow up after two years was biannual. During each follow up a rigid zero degree 4mm endoscope was introduced into the mastoid cavity and it was examined for discharge and factors responsible for discharge if any were noted, and entered in a predesigned proforma. At the end of the study period, data from all the patients was studied and analysed.

Results One hundred and sixty nine patients were included in the study. There were 101 males and 68 females. The age range was 7 to 55 years with a mean age of 24.37 years. The mean follow up was 4.2 years. A total of 41 patients (24.26%) had discharging mastoid cavity. The causes for discharging mastoid cavity (n=41) were as follows (Table 1).

Tympanic membrane perforation with exposed middle ear mucosa and open eustachian tube – 32 patients (78.04%).

Meatal stenosis – 25 patients (60.97%).

High facial ridge – 20 patients (48.78%).

Granulations in mastoid – 13 patients (31.70%).

Residual cholesteatoma – 9 Patients (21.95%).

Anterior buttress – 4 Patients (9.75%).

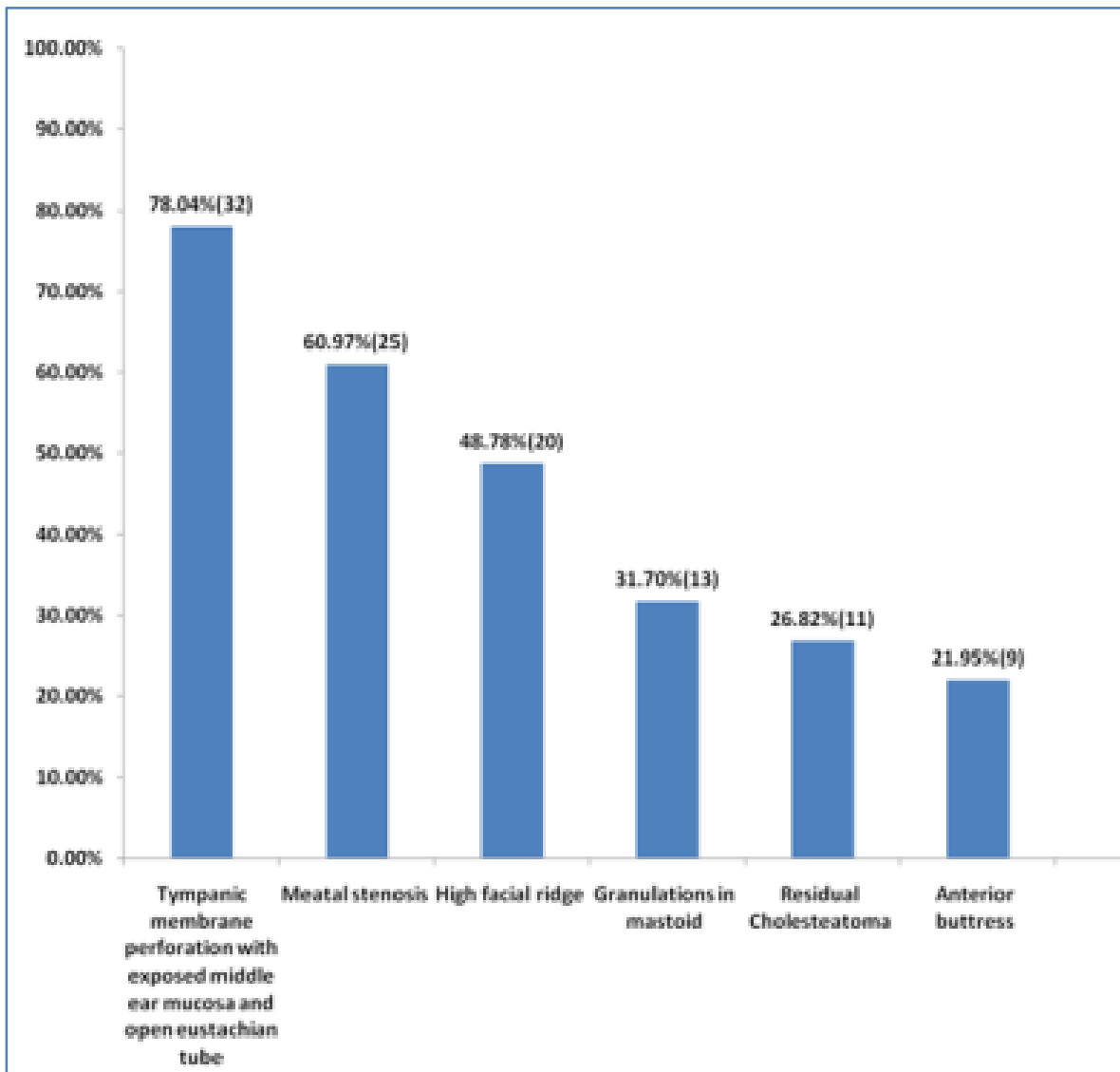


Table 1: Causes for discharging mastoid cavity (n=41)

DISCUSSION: A long term follow up of patients undergoing canal wall down mastoidectomy is essential to detect failures such as discharging mastoid cavity.

Twenty to sixty percent of patients can have continuous or intermittent drainage from their mastoid cavity.⁽²⁾ Forty one (24.26%) patients in our study had discharging mastoid cavity. A careful analysis revealed a few important factors which led to this sequela.

Tympanic membrane perforation with exposed middle ear mucosa and open eustachian tube. The middle ear mucosa and protympanum is covered by the drum head and is normally not exposed to the external environment. Cholesteatoma and granulations destroy the tympanic membrane which is reconstructed during a modified radical mastoidectomy. If the graft does not take resulting in a tympanic membrane perforation, the exposed middle ear mucosa and protympanic mucosa continue to secrete mucous into the mastoid resulting in intermittent or persistent drainage (Fig. 1).

ORIGINAL ARTICLE

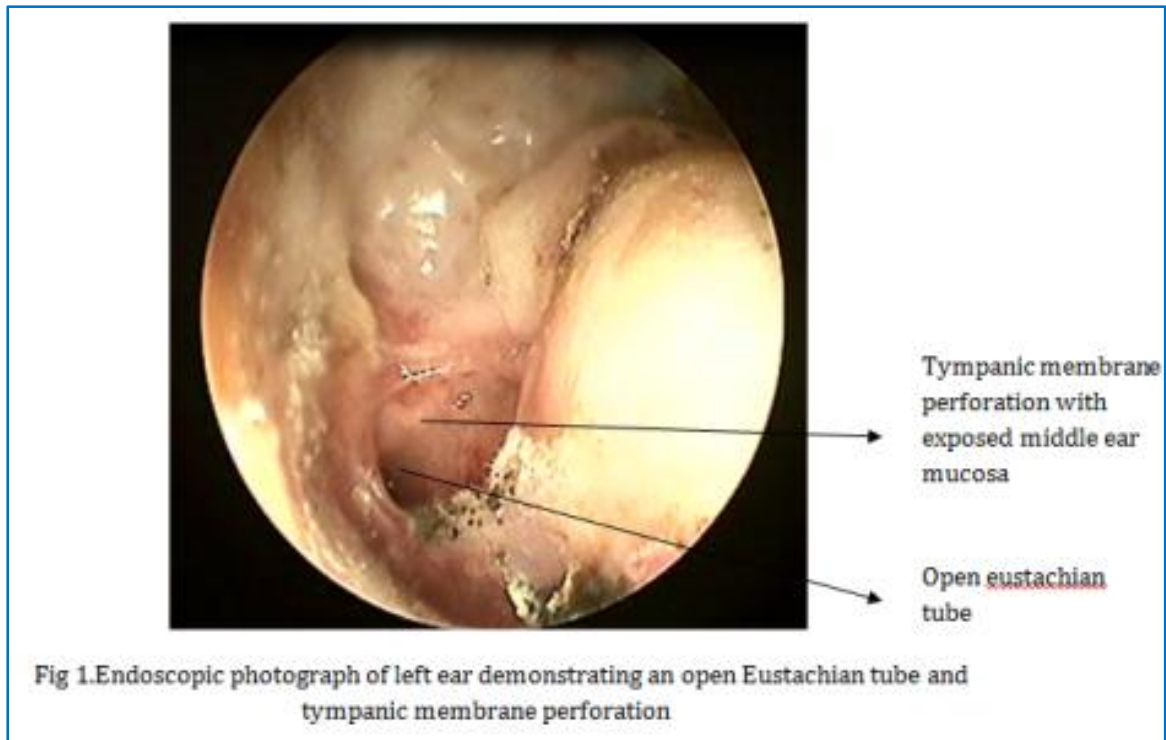


Fig. 1

In addition middle ear mucosa may grow into the mastoid bowl resulting in mucosalization and persistent otorrhea. Thirty two (78.04%) patients in our study had this condition resulting in a discharging mastoid cavity. Bercin,⁽³⁾ reported an incidence of 52.4% in his series (Table 2).

	Present study	
Tympanic membrane perforation With exposed middle ear mucosa and open Eustachian tube	78.04%	52.4% (Bercin, 2009)
Meatal stenosis	60.97%	70% (Sade, 1982) 20% (Al Mayaly, 2007) 84% (Kasenomm, 2013) 57.69% (Ayubi, 2014)
High facial ridge	48.78%	80% (Sade, 1982) 28% (Al Mayaly, 2007) 66.7% (Bercin, 2009) 98% (Kasenomm, 2013) 69.23% (Ayubi, 2014)
Granulations in mastoid	31.70%	78% (Al Mayaly, 2007)
Residual cholesteatoma	21.95%	9% (Palmgren, 1979) 28% (Al Mayaly, 2007) 86.6% (Ayubi, 2014)
Anterior buttress	9.75%	71% (Bercin, 2009)

Table 2: Comparison of present study with similar studies

ORIGINAL ARTICLE

Meatal Stenosis: This is an important cause for failure of modified radical mastoidectomy resulting in a discharging mastoid cavity. We had 25 (60.97%) patients having a narrow meatal opening (Fig. 2).

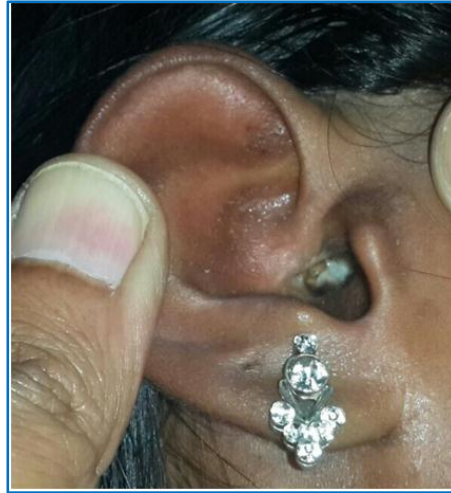

Fig. 2: Right ear showing meatal stenosis

Seventy percent of patients with a narrow meatus in Sade's study,⁽⁴⁾ also presented with a discharging mastoid cavity. Kasenomm,⁽⁵⁾ reported meatal stenosis in 84% of patients undergoing revision surgery for discharging mastoid cavity. Asian studies, Al Mayaly,⁽⁶⁾ from Qatar in his series found inadequate meatoplasty in 20% of patients. Ayubi,⁽⁷⁾ from Faisalabad, Pakistan in 2014 mentioned stenotic meatus as an important cause for a wet ear after a modified radical mastoidectomy. It was found in 57.69% of their patients (Table 2). A narrow meatus results in poor aeration of the mastoid bowl resulting in moisture accumulation which predisposes to fungal and bacterial infection. A small meatus also leads to retention of debris and creates difficulty for the surgeon to clean the cavity. The otologist must fashion a wide meatal opening with excision of conchal cartilage to achieve a wide meatus (Fig. 3).

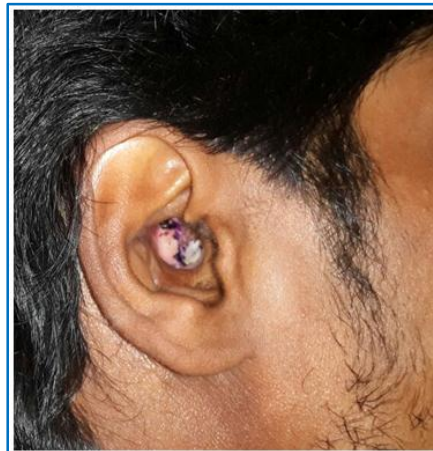

Fig. 3: Right ear demonstrating a wide meatal opening

ORIGINAL ARTICLE

High Facial Ridge: A high facial ridge (Fig. 4) is a mechanical barrier which prevents self-cleansing action leading to retention of debris, infection and drainage.⁽⁸⁾

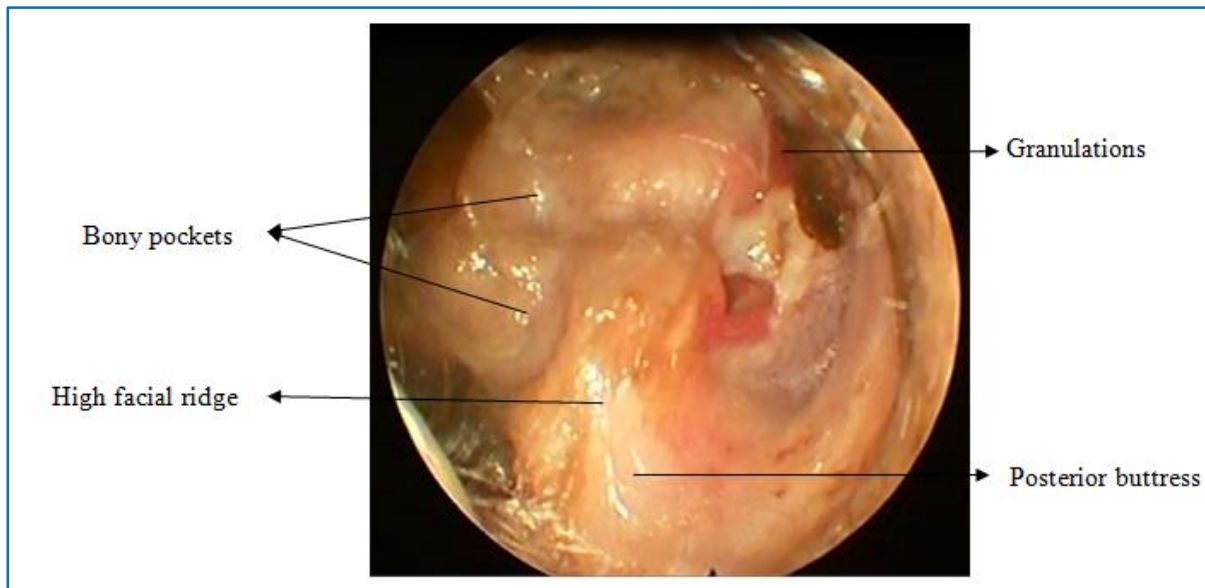


Fig. 4: Endoscopic photograph of discharging Right mastoid cavity

Cleaning the mastoid cavity behind the high ridge is also difficult. Twenty (48.78%) cases in our series had this factor which resulted in cavity drainage. Bercin,⁽³⁾ and Kasenomm,⁽⁵⁾ report an incidence of 66.7% and 98% respectively of high facial ridge leading to discharging mastoid cavity in their study. Eighty percent of patients with a high facial ridge had discharging mastoid cavity in Sade's study.⁽⁴⁾ Al Mayaly,⁽⁶⁾ and Ayubi,⁽⁷⁾ reported a high facial ridge in 28% and 69.23% of patients respectively. Ear surgeons especially beginners are reluctant to lower the ridge adequately for fear of injuring the facial nerve. This can be overcome by learning the anatomy of the temporal bone through repeated cadaveric temporal bone dissections. During surgery the facial ridge must be lowered to the level of the vertical segment of the facial nerve.

Granulations in the mastoid (Fig. 4): Granulations in the mastoid develop in areas where diseased residual cells are present.^(9,10) These are the tegmen plate, sinodural angle, retro labyrinthine, retro facial and tip cells. Seventy eight percent of patients in Al Mayaly's,⁽⁶⁾ study had granulation tissue in the mastoid resulting in continuous drainage from the mastoid bowl. Hence all diseased cells must be meticulously exenterated during surgery.

Residual Cholesteatoma: Cholesteatoma matrix left behind intentionally or inadvertently can lead to a draining ear. If matrix is adherent to the dura, stapes or the facial nerve sheath, it should be left behind and removed later at a second stage operation. Matrix in relatively inaccessible areas such as the sinus tympani may be left behind inadvertently. In our series 9(21.95%) patients had residual cholesteatoma. Six patients had residual disease in the sinus tympani, 2 patients had residual disease involving both sinus tympani and stapes foot plate, in 1 patient matrix was present on foot plate only. Al Mayaly,⁽⁶⁾ quoted an incidence of 28% in his study which is similar to our results. Ayubi,⁽⁷⁾ had a high number of patients with cholesteatoma recidivism-86.6%. This was high when compared to

ORIGINAL ARTICLE

other studies which revealed an incidence of 9%.⁽¹¹⁾ Endoscopes should be used to remove matrix from the sinuses of the posterior wall of the middle ear to prevent residual cholesteatoma.

Anterior Buttress: This should be removed completely to access the epitympanum enabling disease removal and exteriorization. The tegmen tympani should be continuous with the anterior wall of the external auditory canal.⁽¹²⁾ Seventy one percent of patients in Bercin's study,⁽³⁾ had an intact anterior buttress leading to surgical failure. In our series 4(9.75%) patients had remnant anterior buttress leading to failure.

CONCLUSION: The causes for a discharging mastoid cavity are multifactorial and arise due to poor surgical technique. Surgeons should pay attention to complete clearance of disease, creation of a smooth round cavity, lowering of the facial ridge adequately, seal the middle ear from the mastoid bowl by reconstructing the tympanic membrane with a connective tissue graft and create a wide meatus to achieve a dry ear.

REFERENCES:

1. Committee on Conservation of Hearing of the American Academy of Ophthalmology and Otolaryngology: Standard classification for surgery of chronic ear infection. *Archives of Otolaryngology, Head and Neck Surgery*. 1965; 81: 204-205.
2. Saunders JE, Shoemaker DL, Mc Elveen JT Jr. Reconstruction of the radical mastoid. *The American journal of otology*. 1992; 13 (5): 465-469.
3. Bercin S et al. Results of Revision mastoidectomy. *Acta Oto-laryngologica*. 2009; 129 (2): 138-141.
4. Sade J, Weinberg J, Berco E, Brown M, Halevy A. The marsupialized (radical) mastoid. *The Journal of Laryngology and Otology*. 1982; 96: 869-875.
5. Kasenomm P. Intra operative findings of revision canal wall down tympanomastoid surgery. *Acta Oto-laryngologica*. 2013; 133 (8): 826-832.
6. Al Mayaly AS, Hassoun YL, Kadhim RJ. Discharging open mastoid cavity, contributing factors and approach to management. *Qatar medical journal*. 2007; 2 (3): 1-7.
7. Ayubi S, Ahmad S, Ali A. Revision mastoidectomy and otoendoscopy. *JUMDC*. 2014; 5: 61-67.
8. Pillsbury H C, Carrasco V N. Revision Mastoidectomy. *Archives of Otolaryngology Head and Neck Surgery*. 1990; 116: 1019-1022.
9. Nadol JB. Causes of failure of mastoidectomy for chronic otitis media. *Laryngoscope*. 1985; 95: 410-413.
10. Karmarkar S et al. Cholesteatoma surgery: the individualized technique. *The Annals of Otology, Rhinology and Laryngology*. 1995; 104 (8): 591-595.
11. Palmgren O. Long term results of open cavity and tympanomastoid surgery of the chronic ear. *Acta Oto-laryngologica*. 1979; 88: 343-349.
12. Mahadevaiah A, Parikh B. *Surgical techniques in chronic otitis media and otosclerosis*. Bangalore: CBS Publishers; 2008.

AUTHORS:

1. B. Y. Praveen Kumar
2. K. M. Govinde Gowda
3. M. K. Veena Pani
4. Shilpa Tubajirao Hotkar
5. Neelesh Tiwari
6. Thanzeemunisa

PARTICULARS OF CONTRIBUTORS:

1. Assistant Professor, Department of ENT, Mysore Medical College & Research Institute, Mysore.
2. Professor & HOD, Department of ENT, Mysore Medical College & Research Institute, Mysore.
3. Professor, Department of ENT, Mysore Medical College & Research Institute, Mysore.

FINANCIAL OR OTHER

COMPETING INTERESTS: None

4. Junior Resident, Department of ENT, Mysore Medical College & Research Institute, Mysore.
5. Junior Resident, Department of ENT, Mysore Medical College & Research Institute, Mysore.
6. Junior Resident, Department of ENT, Mysore Medical College & Research Institute, Mysore.

NAME ADDRESS EMAIL ID OF THE CORRESPONDING AUTHOR:

Dr. B. Y. Praveen Kumar
#11829, 4th Stage,
2nd Phase, Vijayanagar,
Mysore-570017.
E-mail: entpraveen@yahoo.co.in

Date of Submission: 07/04/2015.
Date of Peer Review: 09/04/2015.
Date of Acceptance: 28/04/2015.
Date of Publishing: 05/05/2015.